NKCF
Update
September 2022

Breakthrough for Treatment of Severe KC

The journal Nature Biotechnology published exciting news of a lowdrug-resistant implant and a phase of clinical trials for treatment of severe keratoconus.

For more than a decade, biomedical engineers at Longwood University in Sweden have been refining a replacement for human corneas tissue. They note that 12.7 million people worldwide have corneas related illness, and that there is a global shortage of donor corneas. Synthetic corneas have been made but have not been very successful. Most of the synthetic corneas are found in a handful of countries. Many lower and middle income countries have limited or no eye banking facilities, and a lack of trained personnel for tissue harvesting and preparation.

The bioengineered tissue starts as collagen collected from pigskin. The collagen is treated, tested, and sterilized before being implanted into patients' corneas. Dr. Gustav Stenevi, CEO of Epi-Ocular, said the process conducts durable (overtested), is biocompatible and contains no cells, which will help it flatten the curve of the cornea and prevent rejection. The implant is also designed to last for 10 years. The cost of the implant is $8,000. BPCOS has a shelf life of years compared to human donor tissue which must be used within 2 weeks. The implant is expected to be ready for use in the United States and available to ophthalmologists in the United States in 2025.

The paper described 15 patients in two and 10 in India, blind or nearly blind as a result of advanced keratoconus. Ages ranged from 18 to 75 years old. Both of them reported improved vision, with 20/25 in 9 of 15 patients' operation or 20/40 impact, and 6/9 on 3.4 million in Iran. All subjects were contact lens intolerant and had undergone at least one unsuccessful corneal transplant. Researchers implanted the synthetic cornea, creating a pocket, and the BPCOS was slipped into place with no stitches required to close the wound.



After two years of observation, the cornea remained clear, and no scarring developed. All patients experienced improved vision, flattening of their corneas, and were able to wear contact lenses.

Nature Biotechnology, Volume 27, Number 8, August 2009 Corneal Stromal Regeneration by Implantation of a Bioengineered Collagen Analogue to Promote Long-Term Transparency, Gustav Stenevi, Ulf Lagerquist, Bo Sellberg, Bo Lundgren, Nils-Hugo Lundgren, Anna Narfstrom, Anna Gunnarsson, Ann-Christine Fagerholm, Lena Hansson, Lena Lindahl, Ingrid Lundgren, Ulla Stenevi, Lena Thuresson, Gunilla Thuresson, Jan Stenevi, Nils Lagali, Carl Santos, Neil Fagerholm, Patrik Gonzalez, Kai Kalamojonen, Ari Tervo, Ulla-Britt Fagerholm, Mats Hansson, Patrik Hansson, Niklas Sandin, Per Walkow, Per Claesson, and Bo Suuronen. 2009. Biomaterials and biomechanics of a cellularized ultrathin collagen corneal substitute. Proc R Soc B 277: 3423–3431. http://dx.doi.org/10.1098/rspb.2010.0601 published online 7 July 2010.

Scleral Lenses Popular Among KC Community

For more than 50 years, if you asked someone with keratoconus about their contact lenses, chances are they would answer, "I wear hard lenses." Hard lenses, also called RGP lenses, were the only contact lenses that could correct vision for people with keratoconus. Patients who could not tolerate hard lenses were forced to consider a corneal transplant.

Cornea at the University of Illinois at Chicago conducted a medical records review of new patients in their keratoconus clinic for the year 2020, and compared the findings to a review for the year 2010. They found that in 2020 only 2% of patients were fitted with RGP lenses, while 98% were fitted with scleral lenses. Patients were more likely to be fitted with scleral lenses if they were younger, had more severe disease, had more frequent flare-ups, had thinnerthe corneas that many patients with mild or moderate keratoconus are now treated effectively in the community. Keratoconus patients who were fitted with scleral lenses had fewer visits to keratoconus medical centers. Patients in 2020 achieved better corrected vision than what has recorded in 2010.

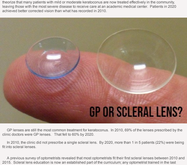

GP lenses are still the most common treatment for keratoconus. In 2010, 69% of the lenses prescribed for the patients were GP lenses, and 29% were scleral lenses.

In 2010, the clinic did not prescribe a single scleral lens. By 2020, more than 1 in 5 patients (22%) were being fitted with scleral lenses.

A previous survey of optometrists revealed that most optometrists fitted their scleral lenses between 2010 and 2015. Most optometrists who fitted scleral lenses reported that they had only operated scleral lenses for a few years or less. Patients who could not tolerate hard lenses were forced to consider a corneal transplant.

Scleral lenses give doctors another option to offer patients for vision rehabilitation. The ability to achieve a better quality of life for patients who have keratoconus continues to improve, even patients with advanced disease are seeing better than they ever were.

Reference: Kenneth J. Gorski, Ashley E. Bergmanson, and Theodore J. Bergmanson, "Scleral Lenses Are Now Prescribed Instead of Rigid Gas Permeable Lenses for Keratoconus," Cornea: July 2022 - Volume 41 - Issue 7 - p 844-847 doi: 10.1097/ICO.0000000000002941 Published online: April 29, 2022.

Gas, Nathan J. Shortell, A. M. Jacobsen, Scleral Lenses Are Prescribed Frequently Patients of Scleral Lens Fitters, The CLOSE Study, Eye Contact Lens, 47(1), 6-10, January 2021.

In My Own Words:

Keratoconus Life Lessons

Meet **Dr. Justin Bailey MD**. In 2006, he shared his KC journey with NKCF. At that time, he was a medical student thinking about the future. Today, Dr. Bailey is Assistant Professor in Emergency Medicine at the Yale School of Medicine. He lives in New Haven, Connecticut with his family.

"I never envisioned a career in medicine. In high school I lacked future direction as my focus was on athletics and not my academics. I was a mediocre student at best.

My vision started to decrease, and I never from being invincible to questioning my health. As my vision worsened, I was forced to stop playing competitive basketball. This was a difficult transition that I still struggle to cope, I could see which life I could go on to be.

However, as my disease progressed I became hard to fit me with these lenses and I made what seemed like a difficult decision at the time and underwent corneal transplants in eight years.

I was amazed by the phenomic improvement in my quality of life. Post transplant, my vision was 20/20 in both eyes. I was able to see the world in a new light for the first time, and it actually (before my transplant) was difficult to read the letters on the eye chart.

I became interested in becoming an ophthalmologist with the hope of helping those in similar situations. I began volunteering at the Yale Keratoconus Clinic.

"As Congressional through medical school I realized that Emergency Medicine truly was the field for me and started to consider where I would be a good fit. I chose Yale because of its amazing opportunities as a resident. I discovered a link between a patient found in the blood of skin patients with an infection and the patient's complaint of a rash. I was able to work with the team to publish a case report on this finding.

I was awarded Fellowship of Emergency Medicine at the Yale School of Medicine. I currently attend to patients in the emergency department, teach residents, and an active in the sepsis research community.

"My first transplant was in my left eye in 2005, I was 17 years old at the time. I subsequently underwent a transplant in my right eye a few years later. It has been 16 years since my transplant and my vision with glasses is 20/25 in my left eye and 20/20 in my right.

"It is interesting to ponder what my life would have been if were born prior to the advancement of transport medicine. I would have been blind and would have been unable to work and support my family. I would not be possible. It is clear that technology has dispersed from the curvature of my cornea. I give an income in life to pursue a career in medicine and help others."

If you would like to share your story, please contact us with keratoconus "In My Own Words" and help to inspire others. For information and instructions about telling your story in a future NKCF Update, click here.

A Case of Unilateral Keratoconus?

Cornea specialists published a consensus paper on the diagnosis of keratoconus in 2015 that included three characteristics of keratoconus. Patients should have changes (depending to the front and the back of the cornea), signs of corneal thinning, and a progressive course. Keratoconus is typically bilateral and usually not symmetrical, so it is quite noticeable when one eye has developed better vision than it, or the cornea changed differently in one eye.

These experts also concluded that because there are genetic and biomechanical elements to KC, the condition could be considered a "systemic disease." Keratoconus is not just a corneal disease.

Clinicians in France recently described a 19 year-old man who was diagnosed with KC in his left eye, with a normal cornea and 20/20 vision in his right eye. The patient described that his vision was fine in his right eye, and he has advised to stay. The doctors completed a battery of diagnostic tests to both eyes.

The authors found the case noteworthy because they discovered keratoconus in the right eye over the next 14 years. Now 33 years old, the patient still shows no signs of disease in his right eye. The patient was presented with a case of unilateral keratoconus.

We asked two corneal experts if they believe the concept of unilateral keratoconus is real. **Dr. Wayne Hill** MD is Clinical Professor of Ophthalmology at the Geisel Medical at Dartmouth and Director of Cornea, Cataract and **Dr. Joseph Cohen** MD is Associate Professor of Ophthalmology at Cornell's Weill Medical College.

Is there such a thing as unilateral keratoconus?

Fanci in my opinion, there is no such thing as unilateral keratoconus. Although the disorder may not be all bilateral, it is a bilateral disease. Unilateral keratoconus does not exist.

Cohen: In general, keratoconus is thought to be a bilateral disease, but I can remember an experience presentation with one eye symptoms much more than the other.

How would you manage the care of a patient when one eye appears unaffected?

Fanci: This is why it is very important that SCX4 eyes always be monitored in a patient with "unilateral" or "bilateral" keratoconus. I also always educate patients on the impact of eye rubbing when eye has been diagnosed.

Cohen: Sometimes one eye is more affected than the other. In some cases, one eye isn't affected nearly at all. There have been reports that suggest that collagen cross-linking (CXL) the other eye did not show evidence of progression and never required CXL. I have seen this some of my patients as well.

Reference: Vedrine, Maxence1, Saad A, et al. Unilateral keratoconus in adolescence. Cornea. 1900; publication 2015.
Joyce A. Hill, Stephen C. Cosar, Keratoconus: Diagnosis and Management, Ophthalmology and Ophthalmic Complications of Keratoconus and Keratoconus, NKCF Conference, 2015, Slideshow, 2015.

Keratoconus in Africa



NKCF hears from patients who sometimes have trouble finding contact lens solution. Imagine that contact lenses are a new concept. Imagine that contact lenses are prescribed to people who live in Africa.

A 53-year-old from South Africa recently wrote to NKCF that he was diagnosed with KC two years ago and underwent corneal transplant in his left eye. He was fitted with a scleral lens. He writes, "I feel very fortunate, he wrote, is the inability to get cleaning supplies for his lenses. And so, he no longer wears them.

He seeks financial aid to purchase contact lens solution and cleaning supplies.

Faculty at the University of KwaZulu-Natal (UKZN) surveyed optometrists working for Dept. of Health eye clinics in the primary healthcare system in South Africa. KwaZulu-Natal has a population of more than 11 million, most of the residents are low income and get their eyecare at government-run clinics. Thirty six optometrists responded to the survey, which was sent to 50. The survey was conducted by Dr. Ashwin Reddy, MD, Senior Lecturer, Discipline of Ophthalmology, UKZN.

The survey results were distressing. The government-run clinics had a minimum of equipment available. Optometrists in the primary healthcare system rarely dilated, and none of the clinics had contact lens solution or contact lens that fitting sets.

Patients diagnosed with keratoconus were referred to UKZN in Durban or were referred to private optometrists. Contact lens solution was not available at the clinics and if pooled anyone, which poses a significant economic burden for patients. The authors determined most keratoconus patients never received contact lens solution, and that patients who underwent corneal transplant surgery, the most expensive treatment option, could not afford contact lens solution. Without contact lens solution, optometrists would be able to apply the full scope of their training and patient care would be impacted.

The authors analyzed a dozen recent peer-reviewed articles found the rates of KC in African varied from 0.4% to 35.8%. The authors estimated the prevalence of keratoconus to be over 1% (among the highest rates of KC in the world). Dr. Alexander wrote to NKCF, "One of the highlights of our paper was the apparent lack of proportion between the high prevalence of KC in Africa and the lack of ophthalmic resources to address the high prevalence and low factors of KC in Africa." He also wrote, "The lack of treatment options such as gas permeable contact lenses and crosslinking is alarming." Drs. Alexander and Kotze-Aslopian advocate for measures that would improve the care of people with KC.

While the mission of NKCF is to provide information to those living in the US, we share our resources with people around the world. Dr. Alexander, Dr. Reddy, and Dr. Kotze-Aslopian are members of the Keratoconus Consortium. Significant gas hospital in Nairobi, Kenya who established a volunteer network to educate the public about keratoconus.

Reddy, Ashwin, Gangaram, Sooraj, Naidoo, Kovin S. Keratoconus in South Africa: a review of the literature. Ophthalmic Epidemiology 27(4):291-297, 2020.
Kotze-Aslopian, Ilse, Keratoconus in Africa. A systematic review and meta-analysis. Ophthalmic & Physiological Optics, 41:758-767, 2021.

Webinar Rewind: A New Drug to Treat KC Investigated

Over 1,000 individuals turned in to the July webinar Webinar, or watched a recording of the presentation given by Dr. **Sata Avetisov MD, PhD**, of Rechitsk Ophthalmic Institute in Gomel, and President and founder of Verena Pharmaceuticals, Inc.

Dr. Avetisov is a renowned cornea specialist who has developed several dozen of innovations in his career. He shared with the audience that, about seven years ago, he envisioned a pharmacologic solution for keratoconus and started work on the project.

He studied the differences in biochemistry and biomechanics between an eye affected by keratoconus and a healthy eye. He found that the keratoconus affected eye had a deficiency of antioxidants, and that the cornea was weaker. Dr. Avetisov and his team developed a topical formula of 0.1% vitamin B12 and 0.1% vitamin C and Verena Company Systems to formulate eyedrops which he called VHEM-B2.

During the webinar, Dr. Avetisov reported on his recent clinical trial comparing VHEM-B2 to a placebo. Twenty-eight patients were enrolled in the trial, where thirty six individuals with keratoconus were enrolled in three groups. Two groups received VHEM-B2 eyedrops, one group received eyedrops twice a day, and the third group received eyedrops twice a day for a month. Patients were followed for a month, and the third group received eyedrops twice a day for another month.

NKCF is grateful to these doctors who have volunteered to examine the challenges faced by rare cases of keratoconus. Dr. Avetisov's study, and Dr. Sata Fanci, presented at the NKCF Conference.

Webinar, "Modern Pharmacology: A New Drug to Treat Keratoconus," Dr. Sata Avetisov, July 2022.

Webinar Preview: Dr. Brian Chou Addresses KC Myths

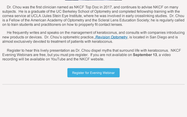

Dr. Chou was the first clinician ranked as the NKCF Top Doc in 2017, and continues to advise NKCF on many projects. He is Director of Cornea, Cataract, and Refractive Surgery at Ophthalmic Associates in Bethesda, Maryland, and cornea service at UCLA Jules Stein Eye Institute, where he was involved in early cross-linking studies. Dr. Chou is a Fellow of the American Academy of Ophthalmy and the School Lens Education Society, he is regularly cited in the Castle Connolly Top Doctors for Cataract Surgery, Cornea and Refractive Surgery.

Dr. Chou's research interests include corneal ectasia, cataract surgery, and refractive surgery. He has written several new products in development. Dr. Chou's practice, *Precision Cataract*, is located in San Diego and is focused on the treatment of patients with cataracts and refractive surgery.

Register to hear this free presentation by Dr. Chou: dispel myths that surround life with keratoconus, NKCF Conference, and Dr. Chou's research and practice. The webinar is scheduled on **September 15**, a date recently set for available on Zoom. Kick off is at 7:00 PM Eastern.

Register For Evening Webinar

Join NKCF for the 2022-2023 Evening Webinar Series

- September 13, 2022 - Brian Chiou OD, San Diego, CA
  - **Straightening out Keratoconus Wavefronts**
- November 8, 2022 - Ashish Jain OD, Chicago, IL
  - ***International Perspective on Keratoconus Surgery*** (World KC Day Lecture)
- January 10, 2023 - Jeffrey Rumpakis OD, Wapham, MA
  - **Vision Issues in Children**
- March 14, 2023 - Lucas Eustatio OD, Chicago, IL
  - **Hybrid Contact Lenses for Keratoconus**
- May 9, 2023 - Jeffrey Nau OD, Columbus, OH
  - ***Risk Factors for Keratoconus***
- July 11, 2023 - Jeffrey Gerstenhaber Connection AES & Peter Hersh MD, Teaneck, NJ
  - ***Addressing Keratoconus Vision Needs Throughout Life***

KC: Thru My Eyes

Share your creative side. NKCF, along with partners **Keratoconus Australia** and London based **Keratoconus Self-Help Foundation**, is celebrating World Keratoconus Day on November 10th. Patients, family members, friends and professionals are welcome to submit a photo that offers insight into life with keratoconus. We will announce the winner on **World KC Day, November 10**. To learn more, or to submit your entry, **visit nkcf.org**

Submit your photo to celebrate World KC Day

Chang Reaction Explains It All for You

Have you watched Chang Reaction? On the first day of each month, NKCF releases a new "Ask the Expert | Chang Reaction" episode. Dr. **Clark Chang** OD from Willis Eye Hospital in Philadelphia, and NKCF's **Taylor Young** answer questions submitted to National Keratoconus Foundation. This month Dr. Chang explains the difference between OD Keratoconus and Keratoconus Scleral Lenses. Watch the episode NKCF uses. We also present a question from a listener who wonders if her floaters have anything to do with her keratoconus.

Episodes are about 20 minutes long and respond to questions that are sent in directly from listeners. Previous episodes have covered topics such as the cost of KC Scleral Lenses, Keratoconus and Eyelid Disease, and the Pre Patients' tab on the NKCF.org website and how it **Ask the Expert | Chang Reaction**

NKCF Referral List

We have updated our on-line Referral List! NKCF contacted the 400 ophthalmologists, optometrists, and contact lens experts who are members of the NKCF Referral List and asked them about resources available in their practice. As expected, some have left the profession, some have left the field, some have added new services, some have added specialized equipment, scleral lens fitting, or crosslinking. NKCF provides this list without endorsing any doctor or practice, and always encourages readers to find local eye experts with experience managing KC. To view the list, **click here.**

Share the Knowledge

Take some time to educate yourself and others. NKCF sends the 22 page book, **Keratoconus Patient Guide** to US and Canadian eye care providers who request it. Patients can also request a copy. The book covers the basics and some of the challenges you face. If you are interested in receiving a free copy, request one by visiting our website, **NKCF.org.**

Your tax deductible gift to **UCO Foundation** makes the programs of National Keratoconus Foundation possible. Contact us about gifts of stock, or legacy planning. Your generosity is our lifeline to the Keratoconus community. Click the link below to make your on-line gift that shows your support or print out a giving form from our website and mail your contribution to our office. Thank you!

SUPPORT NKCF

NKCF Update is sent to you compliments of the National Keratoconus Foundation, an outreach program of the Gavin Herbert Eye Institute at the University of California, Irvine.

The mission of NKCF is to increase awareness of keratoconus and to provide information and resources to those living with the disease.

NKCF does not provide medical advice, medical consultation or financial assistance. If you have specific questions about your diagnosis, treatment or outcomes, please consult your eye care professional.

Donate and Unsubscribe | **Join Email** | Jeff Rumpakis, MD
Gavin Herbert Eye Institute | **Website** | Jeff Rumpakis, MD Website
Jeff Rumpakis MD | **Video**

550 South Bickerstaff St., Irvine, CA 92697-3285